

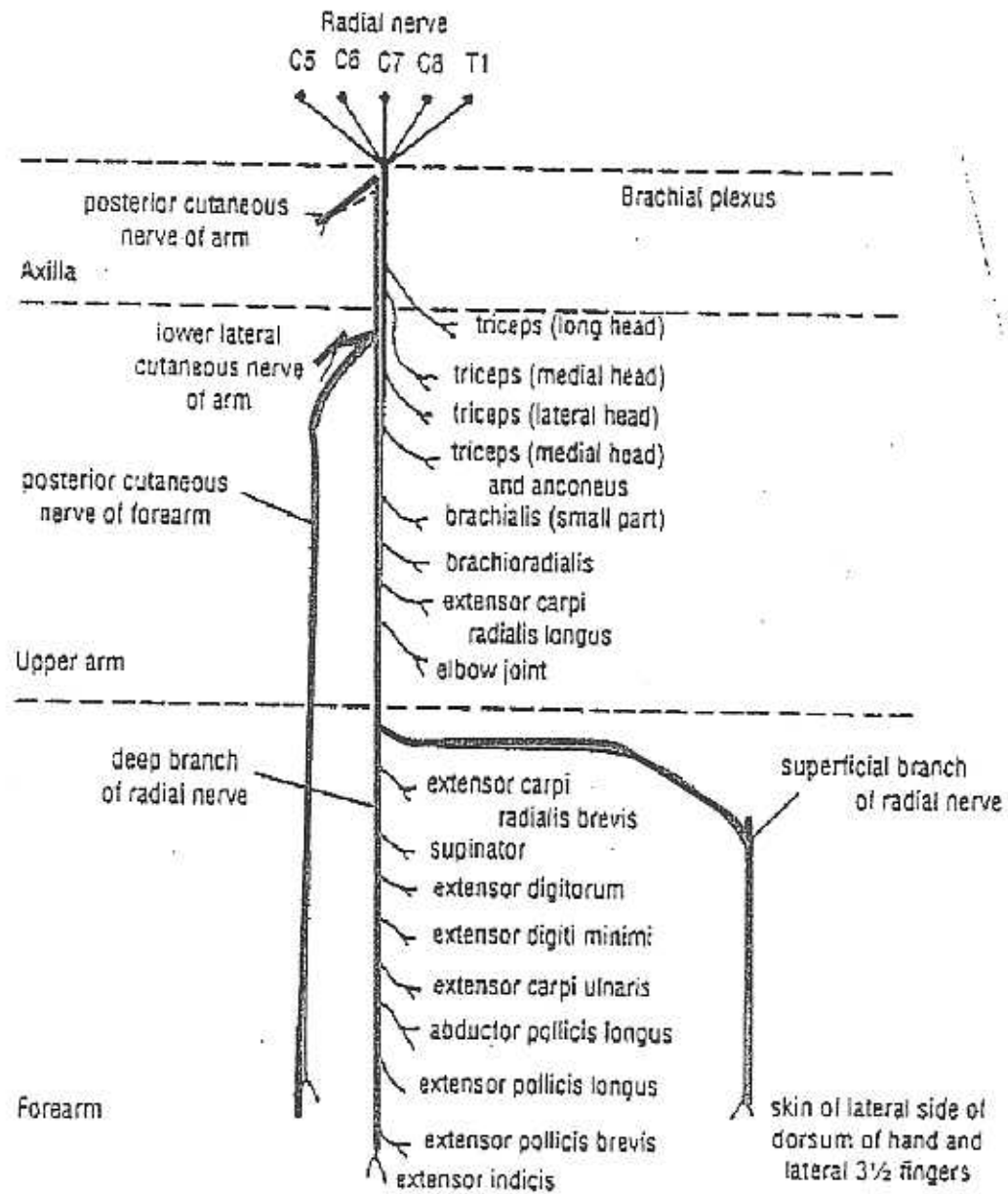FIGURE 9-82 Summary diagram of main branches of radial nerve.

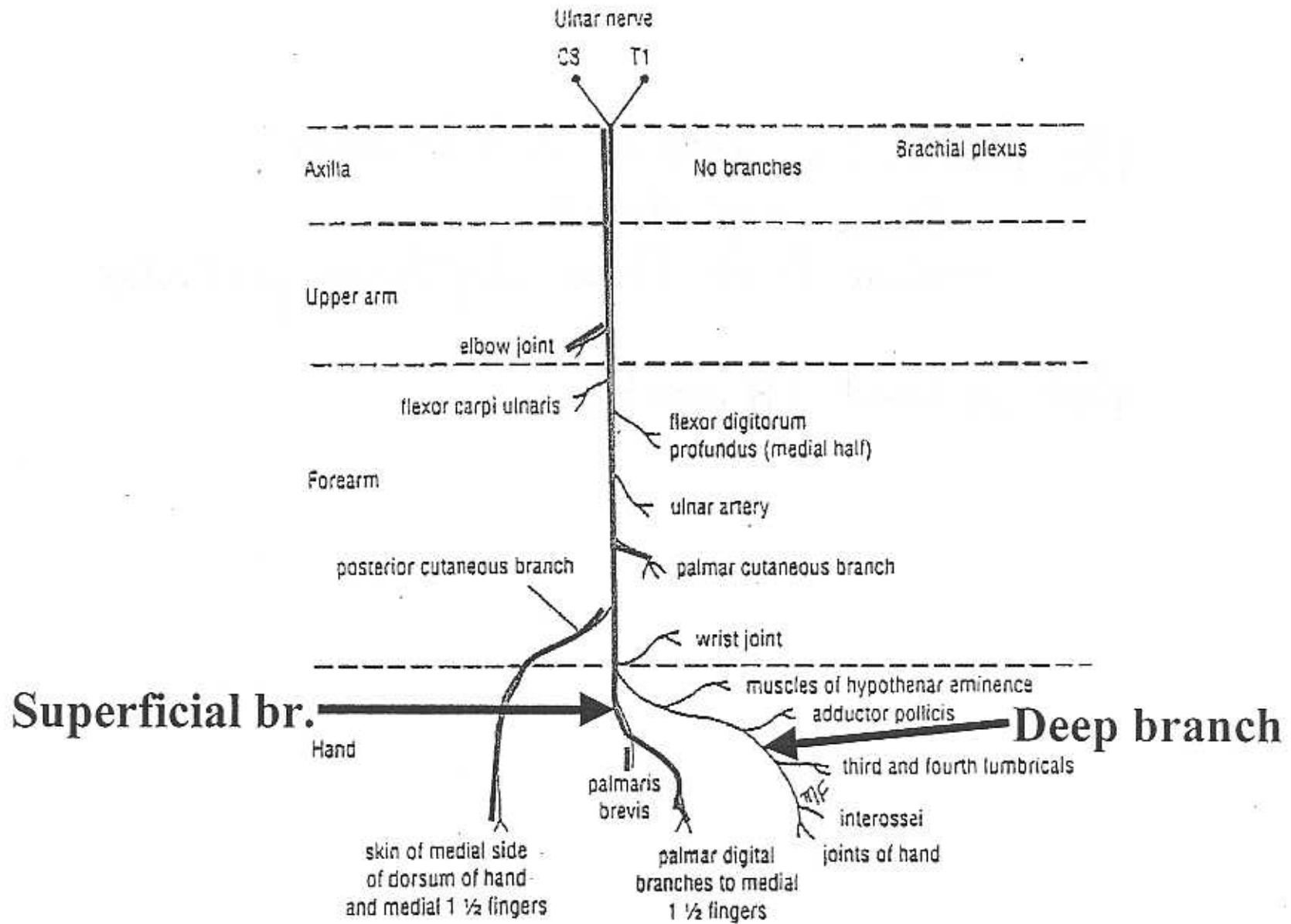


FIGURE 9-87 Summary diagram of main branches of ulnar nerve.

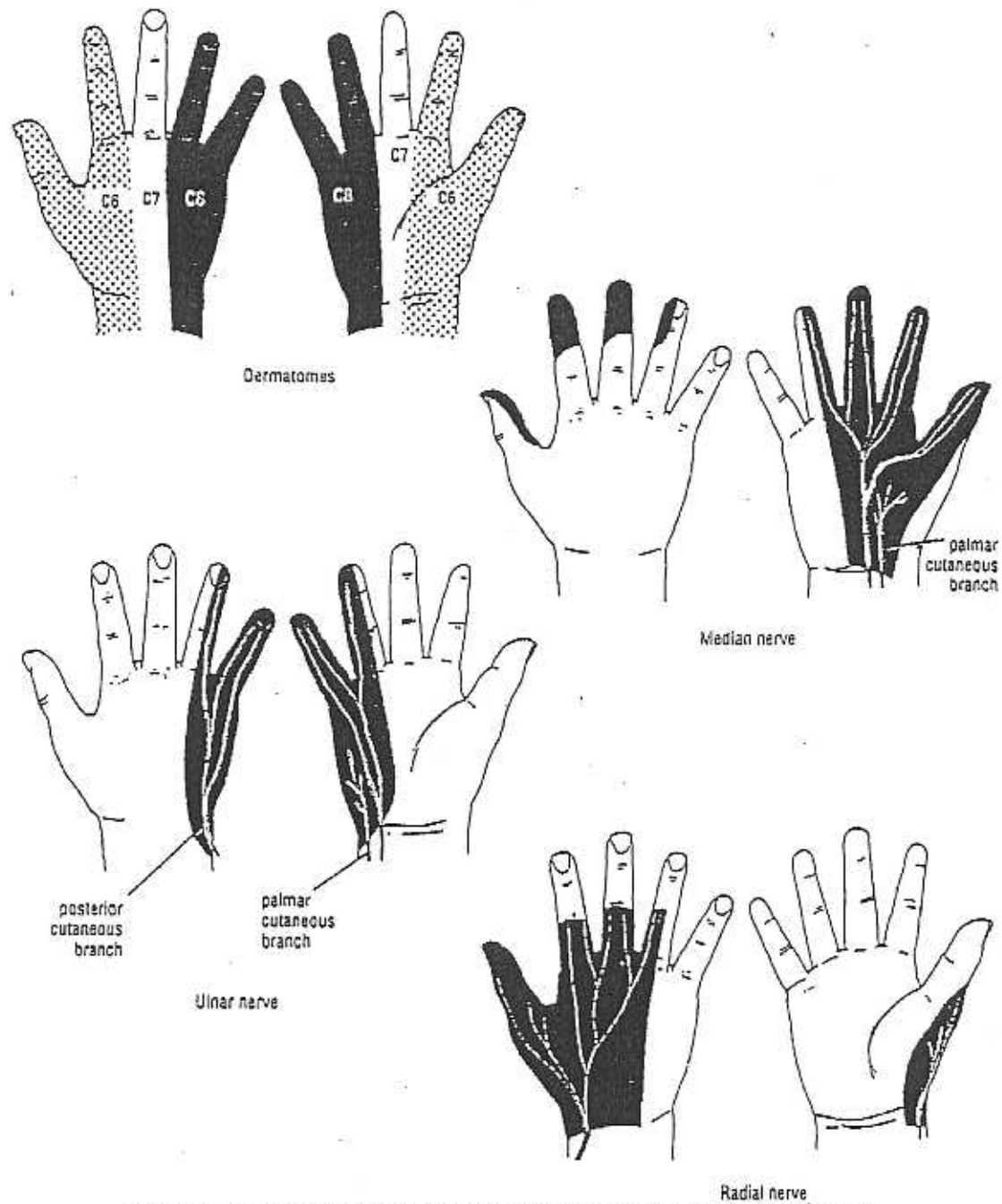


FIGURE 9-83 Sensory innervation of the skin of the volar (palmar) and dorsal aspects of the hand; the arrangement of the dermatomes is also shown.

AXILLARY N

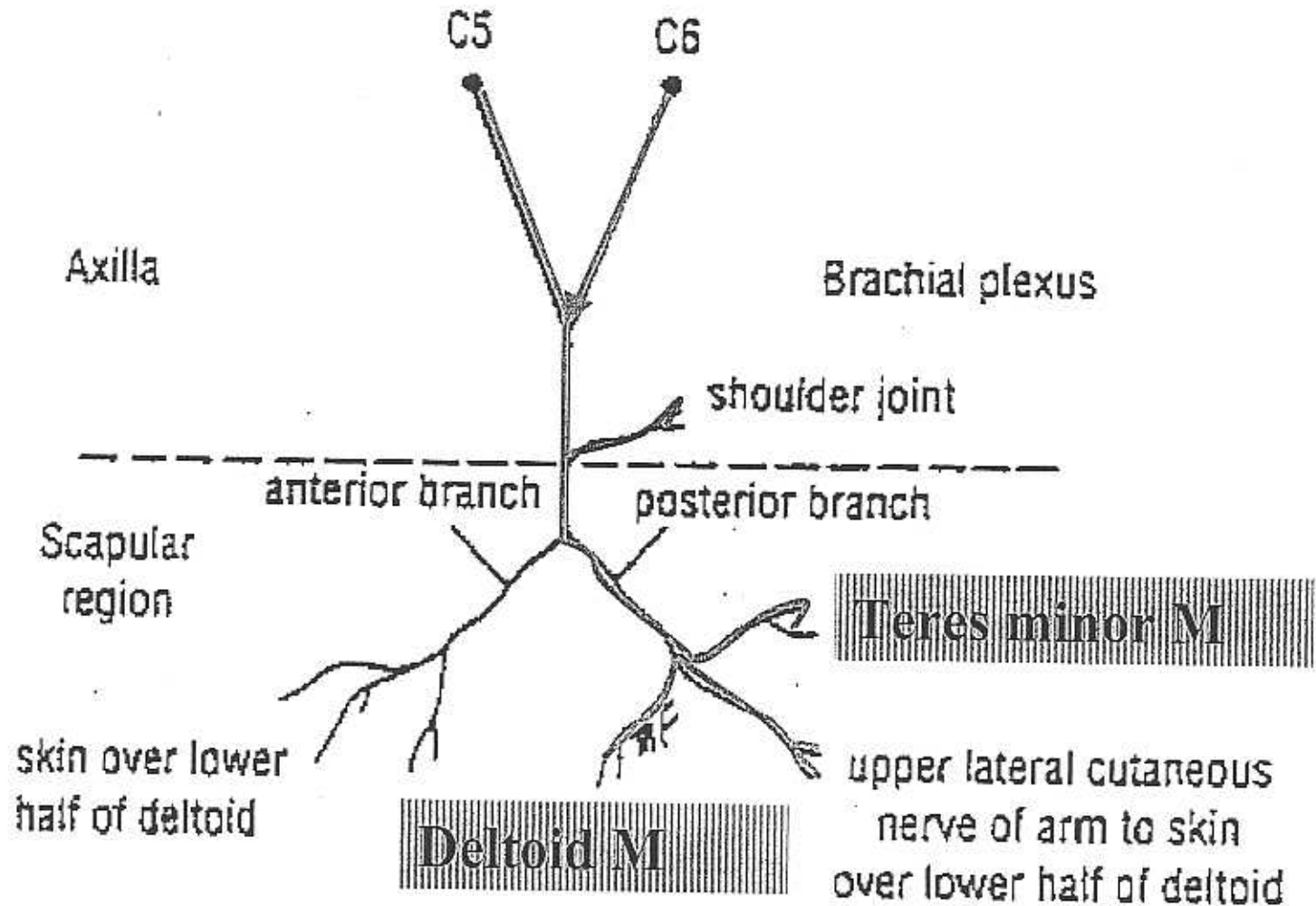


FIGURE 9-81 Summary diagram of main branches of axillary nerve.

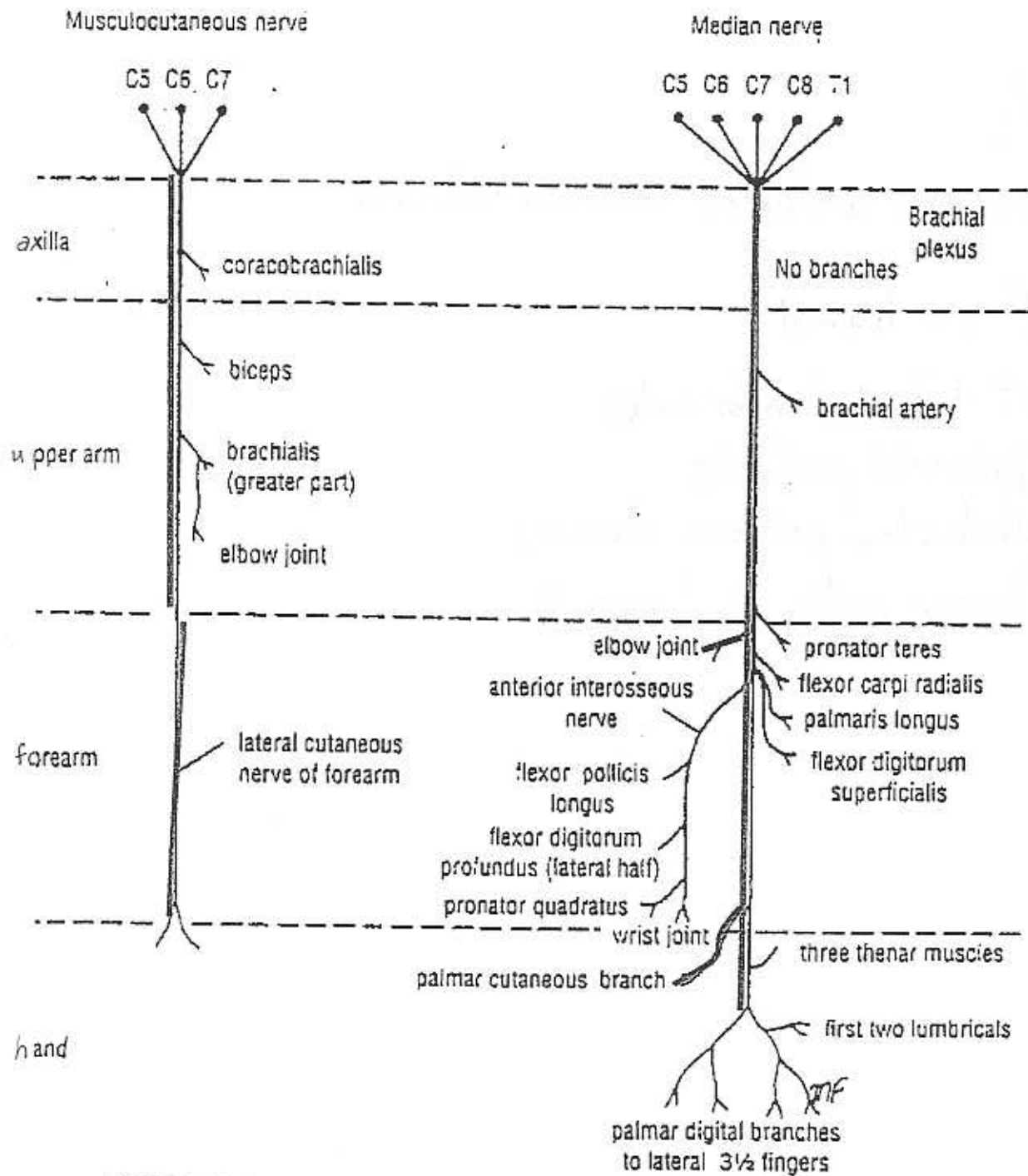


FIGURE 9-85 Summary diagram of main branches of musculocutaneous and median nerves.